

The Benefits of Mobile X-rays in Thoracic and Cardiac Care

Diane Evans, Radiology Education Specialist at Liverpool Heart and Chest Hospital NHS Foundation Trust

CARESTREAM DRX-Revolution Mobile X-ray Unit

The Carestream DRX-Revolution mobile x-ray unit improves workflow and boosts productivity with an intuitive GUI and a long tube head reach – from the centre of the cart to the axis of the X-ray beam – allowing better patient access and more accurate positioning, even in restricted spaces. It's easy to manoeuvre, making a 360-degree turn effortlessly, with an automatic collapsible column which shrinks the system to just over four feet tall, giving complete visibility when moving the system to any location.

The DRX-Revolution features a unique tube-and-grid alignment system that delivers superb X-ray quality and encourages grid use. A powerful 32kW generator, dual focal spot tube and EVP Plus image processing combine to further optimise images, meaning fewer retakes and more support for faster, more accurate diagnoses. The DRX-Revolution also offers prior image review, including techniques and exposure history with its PACS-based query/retrieve capability.

Author

Diane Evans is a Radiology Education Specialist at Liverpool Heart and Chest Hospital NHS Foundation Trust, with more than 25 years' experience in cardiothoracic imaging. In this article she discusses the indications and common problems for performing mobile chest radiography, the benefits of using CARESTREAM DRX-Revolution digital mobile machines, and the importance of using a structured technique to achieve an optimum mobile chest image.

Introduction

At Liverpool Heart & Chest Hospital (LHCH) we undertake approximately 45-50 mobile chest (and some abdominal) x-rays on a daily basis. Most of these mobile examinations are performed on acutely ill, post-operative patients in Intensive Care, Post Operative Critical Care, High Dependency Unit or Coronary Care and often require significant adaptation of technique.¹ However, it is vital that these images are of high diagnostic quality and adhere to IR(ME)R 2000 regulations.²

This article will discuss the indications and common problems for performing mobile chest radiography, the benefits of using CARESTREAM DRX-Revolution digital mobile machines, and the importance of using a structured technique to achieve an optimum mobile chest image. It will also explore the hybrid examination currently utilised at LHCH in performing PA mobile chest radiographs on thoracic patients in the ward environment.

During a complex and competitive evaluation process, The Carestream DRX-Revolution mobile x-ray unit was an outstanding winner, scoring highly on its ease of movement and manoeuvrability. Equally important was the excellent image quality, which is appreciated by the whole MDT. The tube and line visualisation software has been a valued addition to our imaging practice, enabling exemplary small-bore NG tube visualisation, Swan Gantz catheters, and Intra-Aortic Balloon Pumps. We also anticipate that the DRX-Revolution will prove invaluable in future medical trials for new devices such as NG tubes.

Mobile Chest Radiography

Mobile chest radiography performed in the antero-posterior (AP) projection, has always been considered an inferior examination to the more standard PA projection which allows accurate evaluation of the cardiothoracic ratio, comparison between PA examinations, removal of the scapula shadows from the lung fields, and is performed in the erect position on full inspiration at a distance of approximately 6ft from the x-ray tube.³ This 'gold standard' examination reduces cardiac magnification, and the risk of producing a lordotic image as the patient is unlikely to lean backwards. The inferiority of the AP projection lies in the magnification of the heart and widening of the mediastinum and, if performed when the patient is supine, will also lead to alteration of the pulmonary vasculature, whilst the distance from the x-ray tube will also be considerably less than 6ft, which will increase the effect of the beam divergence (ie magnification.⁴) As such, the AP examination (whether erect or supine) should only be performed on critically ill patients.⁵

At LHCH, we employ the high KVp (125Kv) technique for all PA and AP Chest Radiography - PA with the use of a grid, and AP mainly without a grid. This deliberately lowers contrast,

White Paper | CARESTREAM DRX-Revolution Mobile X-Ray Unit

allows better penetration and shorter exposure times, which enables the clinician to envisage the structures of the mediastinum without losing the definition of the lung markings.⁶

Some of the acceptable indications for an AP mobile CXR on critical care patients are as listed below:

- Immediate postoperative cardiac/thoracic surgery
- Insertion of CVC/chest drains/ETT/TPW/IABP/NG tube
- Removal of chest drains – mediastinal and intercostal
- Poor arterial Blood Gases
- Pleural effusion
- Consolidation
- Lobar collapse
- Atelectasis
- Pneumonia/Infection
- Aspiration pneumonitis
- ARDS/pulmonary oedema
- Post resuscitation
- Tamponade

Problems Associated with Examinations on Acutely Ill Patients

Acutely ill patients often require considerable medical support as they may not be haemodynamically stable, and have other co-morbidities. These facts mean the radiographer is presented with difficulties around the safe movement of the patient and accurate detector/patient positioning in order to achieve an optimal diagnostic image.⁷ For example, haemodynamically unstable patients will become hypotensive when raised to an erect position; similarly, those with an IABP (intra-aortic balloon pump) in situ cannot be raised to an upright position of more than 30° due to the large sheath in the femoral artery. The sedation of these patients can also vary, leading to different levels of patient co-operation or occasional distress during the x-ray examination. Accordingly, communication and team working between the nursing, medical staff and radiographers on the Critical Care Unit is crucial in producing a diagnostic mobile chest x-ray (CXR). A brief patient history should be discussed in order to ascertain what movement or position is possible for the patient and, if conscious, what movement the patient can achieve on his or her own. Lifting and moving protocols must be adhered to, ensuring staff and patient safety in addition to Infection Control protocols that involve the radiographers using separate Personal Protective Equipment (PPE) for each patient and placing the detector in a disposable bag. Finally, if the radiographer follows the technique as detailed below, then the resultant image should be one of high diagnostic quality despite being a mobile Antero-Posterior image.

The LHCH Technique – O to U Approach

This is a technique developed over 5 years ago as an aid for inexperienced radiographers.

O – Observe the patient from the end of the bed space.

Observation is often underutilised and is, in my opinion, an essential clinical skill in producing a quality diagnostic image.

The radiographer should observe:

The patient's position in the bed to establish if they are rotated. Hip and Shoulder positions are vital to obtain a 'straight' (not rotated) patient. Can they be moved into the erect position?

Any lines/devices/ECG leads – what is the patient attached to?

The patient's colour, state of mental awareness/conscious level (can they follow a command), what is the respiratory rate?

These questions allow the radiographer to analyse how acutely ill the patient is and whether additional help or positioning aids will be needed to perform the x-ray.

PQ – Position with Quality.

Patients in critical care are often rolled onto their sides to prevent bedsores.⁸ If the patient is rotated in any way, even if they are erect, the image will be sub-optimal, causing various anatomical structures to be projected laterally.⁹ Move the bed mattress to horizontal, and the patient to a completely straight supine position. The back of the bed can then be raised to an almost erect position to allow the patient to be moved forward and the cassette/detector placed behind. If the patient is in a comfortable position, then they are more likely to remain still and co-operate during the examination.

R – Remove ECG leads/ lines/ NG tubes from chest area.

Any artefact is a complete distraction to the pathology on the radiograph and all external lines/leads devices should be moved where possible.¹⁰ For example, ECG leads can be placed around the back of the patient's neck rather than across the front of the chest.

S – Set x-ray tube eg caudal, cranial, canted

It is essential that the x-ray beam is perpendicular to the detector. Observing the x-ray tube from the foot of the bed will prevent any lateral angulation that could result in a rotated image.¹¹

T – Test breathing, may need to reposition

Shallow inspiration is problematic in critical care patients, especially if they are conscious and in pain.¹² Yet, an AP radiograph taken with minimal inspiratory effort can mimic atelectasis or infection.¹³ Encouraging a conscious patient to practice their inspiratory breath-hold can enable better inspiration on exposure, and allows the radiographer to assess the patient's respiratory pattern.

White Paper | CARESTREAM DRX-Revolution Mobile X-Ray Unit

U – Use timing and ‘prep’

The preparation of depressing the exposure switch to commence anode rotation prior to the actual exposure will minimise breath-hold. Radiographers should always use the ‘prep’ part of the x-ray exposure to watch the patient’s inspiration and to ensure the actual exposure takes place at the optimal time.

Following this technique should alleviate the need for repeat exposures and produce excellent diagnostic images such as figures 1 and 2 below:

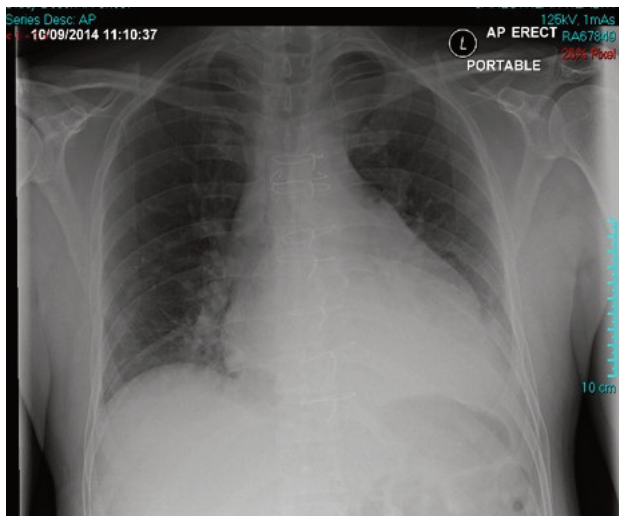


Fig 1

The patient is erect and not rotated. There are no artefacts or ECG leads to distract from the image. The patient has taken a reasonable breath in (to the level of 6 anterior ribs) and collimation is present laterally. All of the area of interest, i.e. the chest, is present.

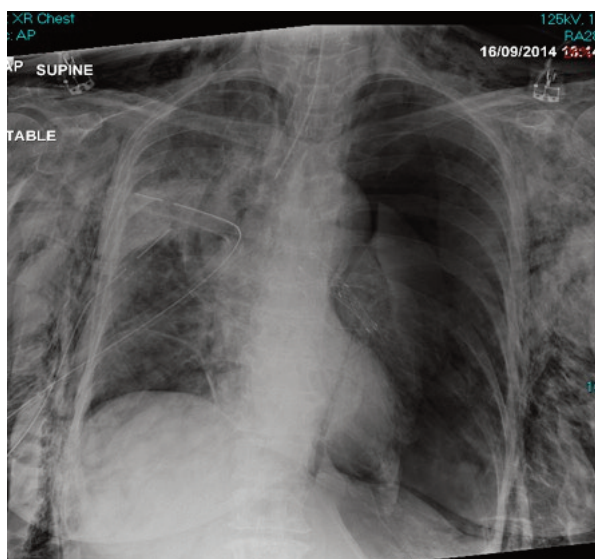


Fig 2

The patient is supine and clearly acutely ill. There is minimal rotation, and ECG leads have been positioned away from the chest area. Notable additions to the image are a right chest drain, an endo-tracheal tube (ETT) and a left bronchial stent. There is collimation present and care has been taken to ensure the image has been exposed during the inspiratory phase of ventilation. The image demonstrates a left tension pneumothorax – note tracheal deviation to the right – in addition to acute onset of surgical emphysema.

Avoiding the ‘Sinful Six’ reasons to reject a mobile AP chest image.

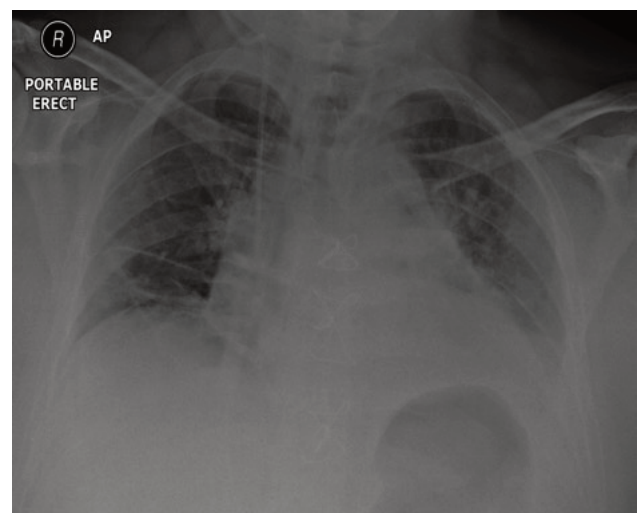


Fig 3. Poor Inspiration

The 6th anterior rib should be seen on an AP mobile CXR and the ‘D’ dome of the diaphragm at the level of the 3rd or 4th intercostal space. Poor inspiration can often mimic atelectasis or collapse, which is misleading for the clinician and thus affect patient management.

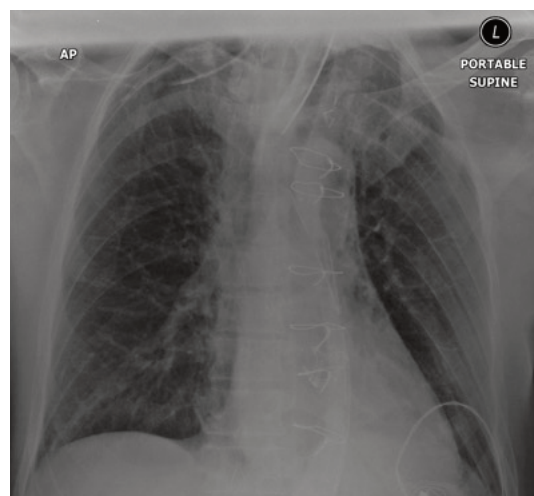


Fig 4. Rotation

White Paper | CARESTREAM DRX-Revolution Mobile X-Ray Unit

Clavicles should be equidistant from the mid-line. Distortion of the mediastinum means the radiological report will be incomplete as the radiologist will be unable to comment on this area.

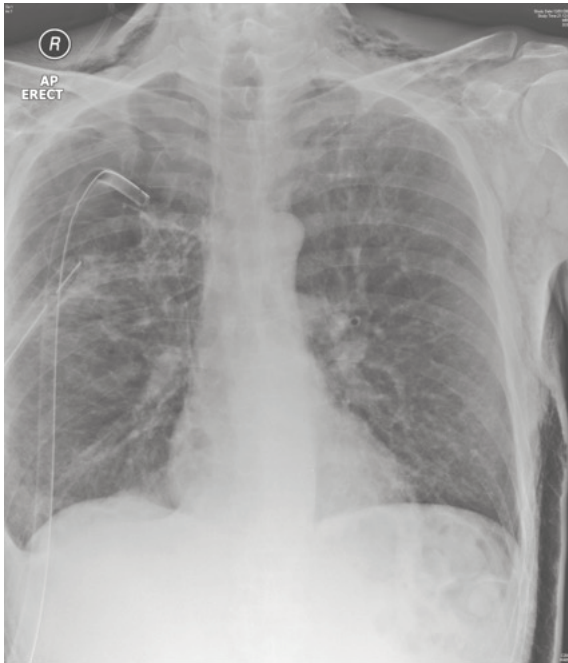

Fig 5. Missed Anatomy

All of the area of interest must be present on the image for it to be considered diagnostic. Due to the poor technique demonstrated above, it is impossible to see the true extent of the residual pneumothorax on the right side.

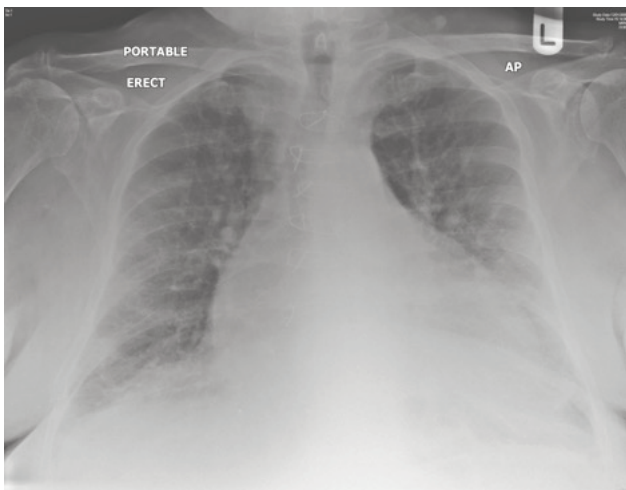


Fig 6. Lordosis

Distortion of the thoracic anatomy will make an accurate diagnosis highly unlikely.

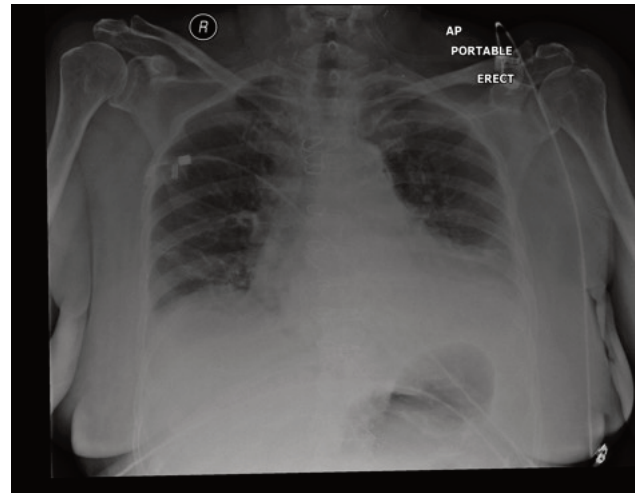


Fig 7. Lack of Collimation

Appropriate collimation is essential to comply with I(RM)ER 2000 regulations. On the above chest X-ray image, both shoulders and upper abdomen can clearly be visualised. These are unwanted, and as such unnecessary body-parts have been irradiated.

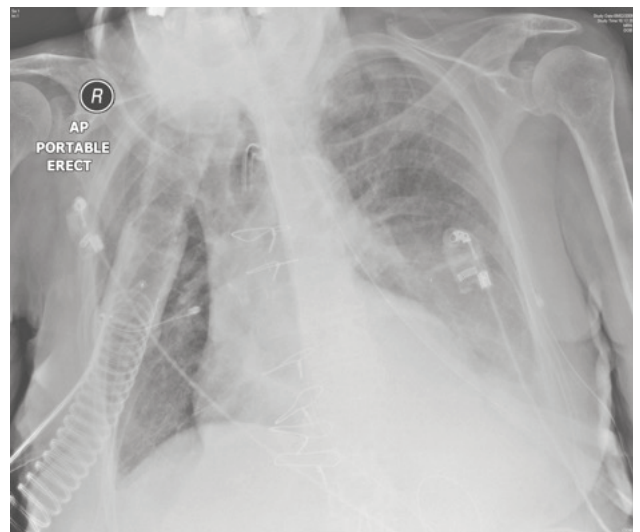


Fig 8. Presence of Artefacts

ECG leads and the catheter mount attachment to the patient's oxygen mask obscure a greater part of the right lung field and part of the left.

White Paper | CARESTREAM DRX-Revolution Mobile X-Ray Unit

The Benefits of CARESTREAM DR and the LHCH Hybrid Mobile Technique

The benefits of DR imaging as opposed to conventional film have been well documented.¹⁴ At LHCH, we are fortunate to have procured four CARESTREAM DRX-Revolution mobile machines with wireless detectors and wireless transfer to PACS. Images can be duplicated and windowed to visualise lines, giving two images for one radiation exposure.

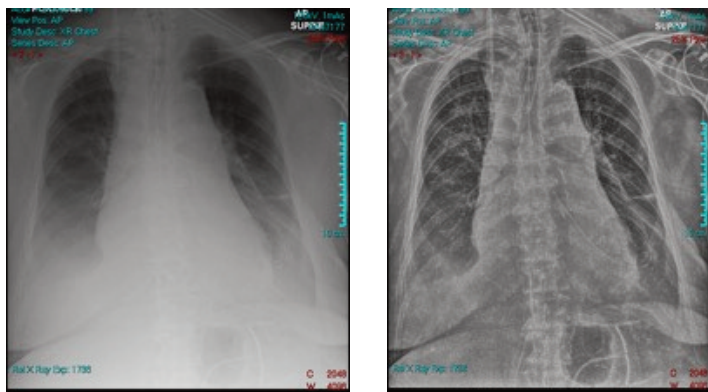


Fig 9.

Clinical staff appreciate this instant imaging, which can expedite patient management.

A Patient-Focused Approach

In conjunction with our main thoracic ward, we have also established a satellite x-ray room which complies with IRR 99 and IR(ME)R 2000 regulations, utilising the **Carestream DRX-Revolution** mobile machines, a portable detector stand and stationary grid. This room is employed for use on a daily basis, yet does not inconvenience the ward as the **Carestream DRX-Revolution** is always removed leaving the room available for patient treatments.

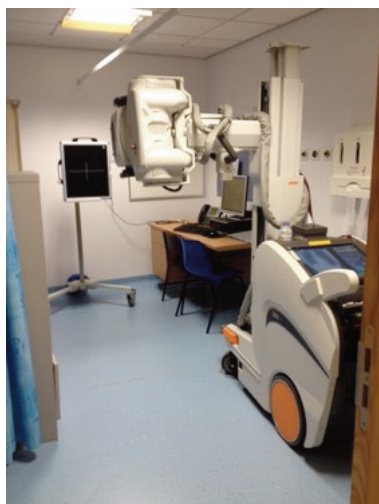

Fig 10.

Our thoracic patients who are unable to leave the ward due to ECG monitoring, or patient-controlled anaesthesia (PCA) for example, can then be x-rayed in the ideal PA position regardless of chest drains and other devices. Without the advantage of the satellite room, these patients would have x-rayed at their bedsides in the sub-optimal AP position.

We have had a very positive response since introducing this way of working, not least from the patients themselves, who appreciate not leaving the ward in order to be wheeled through a potentially draughty corridor in full view of other clinical staff, visitors and patients. This has also released our patient transfer staff to concentrate on the CT/MRI patients to aid an efficient, but extremely busy cross-sectional service. Indeed, for a hospital that has consistently been rated the premiere hospital for patient care over the last eight years, our **Carestream DRX-Revolution** units have been a successful and innovative addition for the effective diagnostic imaging of our critical care patients.

Conclusion

It is imperative to utilise clinical skills, clear communication, correct radiographic technique and teamwork when considering mobile chest radiography on the critically ill patient. In doing so, we can achieve an optimal diagnostic bedside image for the benefit of the reporting clinician, surgeons and, ultimately, for the clinical management of these acutely ill patients.

References

1. Clark, K. (2005) Clark's positioning in radiography (edited by S. Whiteley et al.) London: Hodder Arnold Chapter 12
2. [www.gov.uk/government/uploads/system/uploads/attachment_data/file/100000/IRR99_and_IR\(ME\)R2000_regulations_2000.pdf](http://www.gov.uk/government/uploads/system/uploads/attachment_data/file/100000/IRR99_and_IR(ME)R2000_regulations_2000.pdf)
3. G De Lacey et al. (2008) The Chest X-ray: A survival Guide. Saunders Elsevier Chapter 1
4. www.med-ed.virginia.edu/courses/rad/cxr/technique3chest
5. Grainger & Allison (2001) Diagnostic Radiology Vol 1. The post-operative critically ill patient. Chapter 1
6. Interpreting the CXR (2010) Scion Publishing, Stephen Ellis Chapter 1
7. Clark, K. (2005) Clark's positioning in radiography (edited by S. Whiteley et al.) London: Hodder Arnold Chapter 12
8. Ousey, K (2005) Pressure Area Care (Essential Clinical Skills for Nurses. Blackwell Chapter 7
9. G De Lacey et al. (2008) The Chest X-ray: A survival Guide. Saunders Elsevier Chapter 1
10. Clark, K. (2005) Clark's positioning in radiography (edited by S. Whiteley et al.) London: Hodder Arnold Chapter 12
11. G De Lacey et al. (2008) The Chest X-ray: A survival Guide. Saunders Elsevier Chapter 1
12. G De Lacey et al. (2008) The Chest X-ray: A survival Guide. Saunders Elsevier Chapter 1
13. Grainger & Allison (2001) Diagnostic Radiology Vol 1. The post-operative critically ill patient. Chapter 1
14. Interpreting the CXR (2010) Scion Publishing, Stephen Ellis Chapter 1